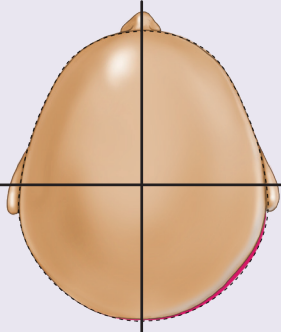
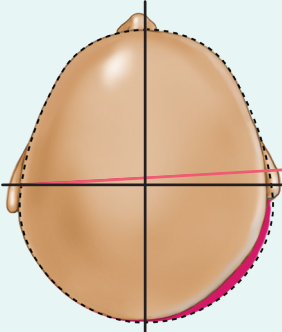
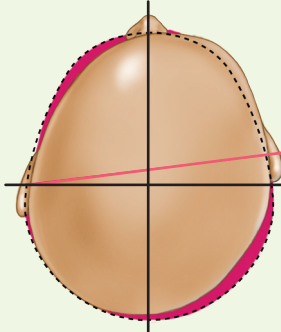
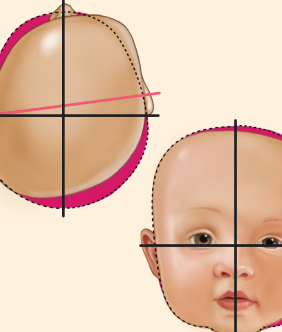
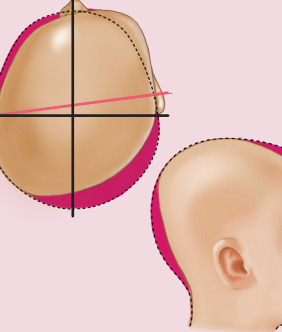


Clinical Assessment of Infant Head Shapes

Referrals for orthotic evaluation are recommended for deformational plagiocephaly Types III-V, and for deformational brachycephaly Types II-III.

Deformational Plagiocephaly (DP) — Primary deformity is asymmetry.

TYPE I — Normal	TYPE II — Mild	TYPE III — Moderate	TYPE IV — Severe	TYPE V — Very Severe
				
CLINICAL FEATURES	CLINICAL FEATURES	CLINICAL FEATURES	CLINICAL FEATURES	CLINICAL FEATURES
<ul style="list-style-type: none"> Minimal posterior flattening 	<ul style="list-style-type: none"> Posterior flattening Minimal ear shift 	<ul style="list-style-type: none"> Posterior flattening Ear shift Forehead asymmetry 	<ul style="list-style-type: none"> Posterior flattening Ear shift Forehead asymmetry Orbital, cheek, face or jaw deformity Frontal and /or parietal sloping 	<ul style="list-style-type: none"> Posterior flattening Ear shift Forehead asymmetry Orbital, cheek, face or jaw deformity Frontal and/or parietal sloping Temporal bossing and increased cranial vault height
CLINICAL RECOMMENDATIONS	CLINICAL RECOMMENDATIONS	CLINICAL RECOMMENDATIONS	CLINICAL RECOMMENDATIONS	CLINICAL RECOMMENDATIONS
<ul style="list-style-type: none"> Repositioning & tummy time Monitor for improvement / progression 	<ul style="list-style-type: none"> Repositioning & tummy time Monitor for improvement / progression 	<ul style="list-style-type: none"> Repositioning & tummy time Refer for orthotic evaluation 	<ul style="list-style-type: none"> Repositioning & tummy time Refer for orthotic evaluation 	<ul style="list-style-type: none"> Repositioning & tummy time Refer for orthotic evaluation

The classification scale shown here is adapted from Argenta¹ and provides a qualitative approach to the identification of infant skull deformities. Mild deformities should be monitored in very young infants (under four months of age) to ensure the deformity does not progress towards greater levels of severity. Moderate and severe cranial deformities should be referred for further orthotic evaluation and/or treatment. All infants with identified neck muscle asymmetry, weakness or tightness should be referred for therapeutic evaluation and/or treatment.

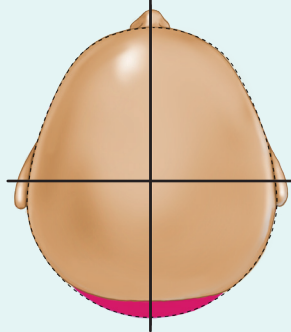
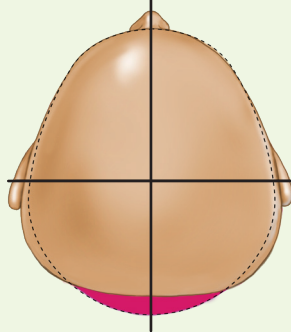
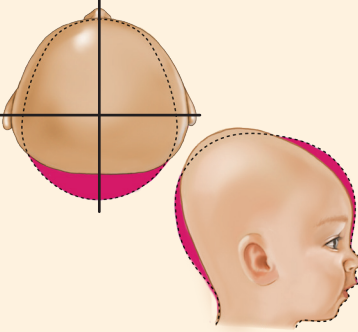
1. Argenta L, David L & Thompson J. (2004). Clinical classification of positional plagiocephaly. The Journal of Craniofacial Surgery 15(3):368-372.



Clinical Assessment of Infant Head Shapes

Referrals for orthotic evaluation are recommended for deformational plagiocephaly Types III-V, and for deformational brachycephaly Types II-III.

Deformational Brachycephaly (DB) – Primary deformity is disproportion.

TYPE I – Mild	TYPE II – Moderate	TYPE III – Severe
		
<p>CLINICAL FEATURES</p>	<p>CLINICAL FEATURES</p>	<p>CLINICAL FEATURES</p>
<ul style="list-style-type: none"> • Central occipital flattening 	<ul style="list-style-type: none"> • Central occipital flattening • Widening of the posterior skull • Frontal flattening or bossing 	<ul style="list-style-type: none"> • Central occipital flattening • Widening of the posterior skull • Frontal flattening or bossing • Frontal and/or parietal sloping • Temporal bossing and increased cranial vault height
<p>CLINICAL RECOMMENDATIONS</p>	<p>CLINICAL RECOMMENDATIONS</p>	<p>CLINICAL RECOMMENDATIONS</p>
<ul style="list-style-type: none"> • Repositioning & tummy time • Monitor for improvement / progression 	<ul style="list-style-type: none"> • Repositioning & tummy time • Refer for orthotic evaluation 	<ul style="list-style-type: none"> • Repositioning & tummy time • Refer for orthotic evaluation

The classification scale shown here is adapted from Argenta¹ and provides a qualitative approach to the identification of infant skull deformities. Mild deformities should be monitored in very young infants (under four months of age) to ensure the deformity does not progress towards greater levels of severity. Moderate and severe cranial deformities should be referred for further orthotic evaluation and/or treatment. All infants with identified neck muscle asymmetry, weakness or tightness should be referred for therapeutic evaluation and/or treatment.

1. Argenta L, David L & Thompson J. (2004). Clinical classification of positional plagiocephaly. The Journal of Craniofacial Surgery 15(3):368-372.